

TRANSVERSUS ABDOMINIS PLANE (TAP) BLOCK

BY KARIM MUKHTAR, MD

Abdominal field blocks have been extensively used for a variety of surgical procedures for many years. They are simple to perform and have a good safety profile. Until recently, these blocks were performed using a blind technique which relied on multiple “pops” as the block needle traversed different fascial planes. This rendered their success unpredictable and required multiple injections of large volumes of local anesthetic drugs to ensure adequate spread.

INTRODUCTION

There has been renewed interest in abdominal field blocks and the quest for a single injection providing widespread analgesia has led to the rapid popularity of the transversus abdominis plane (TAP) block. The description of a landmark technique for performing a TAP block advocated a single entry point, the triangle of Petit, to access a number of abdominal wall nerves hence providing multi-dermatome analgesia. (1) More recently, ultrasound guided TAP block has been described with promises of better localization and deposition of the local anaesthetic with improved accuracy (2).

ANATOMY

Innervation of the anterolateral abdominal wall arises from the anterior rami of spinal nerves T7 to L1. These include the intercostal nerves (T7-T11), the subcostal nerve (T12), and the iliohypogastric and ilioinguinal nerves (L1).

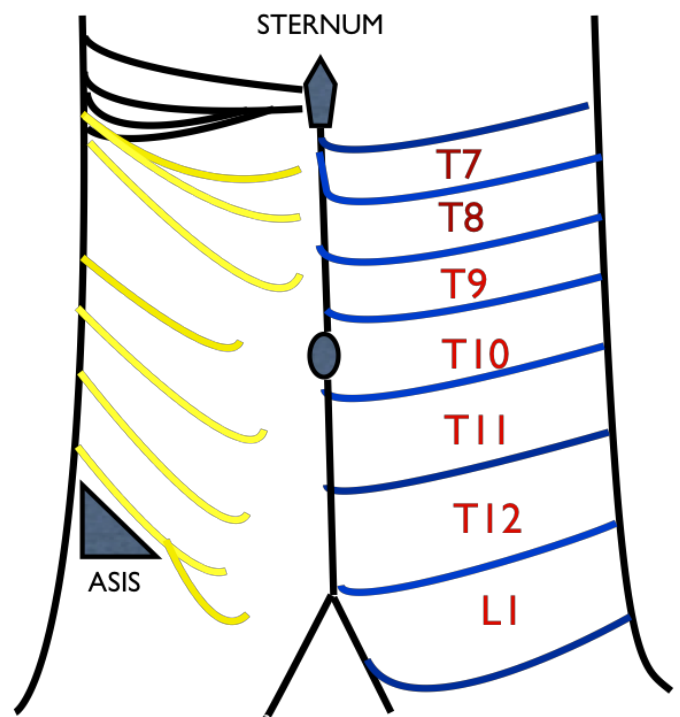


Figure 1. Schematic presentation of the cutaneous innervation of the abdominal wall.

The anterior divisions of T7-T11 continue from the intercostal space to enter the abdominal wall between the

internal oblique and transversus abdominis muscles until they reach the rectus abdominis, which they perforate and supply, ending as anterior cutaneous branches supplying the skin of the front of the abdomen. Midway in their course they pierce the external oblique muscle giving off the lateral cutaneous branch which divides into anterior and posterior branches that supply the external oblique muscle and latissimus dorsi respectively.

The anterior branch of T12 communicates with the iliohypogastric nerve and gives a branch to the pyramidalis. Its lateral cutaneous branch perforates the internal and external oblique muscles and descends over the iliac crest and supplies sensation to the front part of the gluteal region.

The iliohypogastric nerve (L1) divides between the internal oblique and transversus abdominis near the iliac crest into lateral and anterior cutaneous branches, the former supplying part of the skin of the gluteal region while the latter supplies the hypogastric region.

The ilioinguinal nerve (L1) communicates with the iliohypogastric nerve between the internal oblique and transversus abdominis near the anterior part of the iliac crest. It supplies the upper and medial part of the thigh and part of the skin covering the genitalia (3).

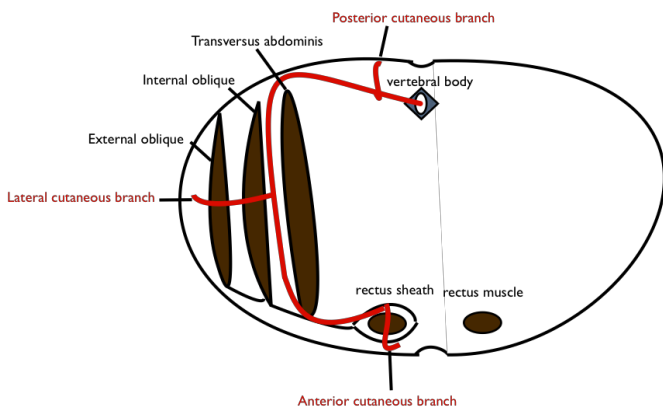


Figure 2. T7 to T12 spinal nerves pathway and branches in the abdominal wall

BLOCK TECHNIQUE

The aim of a TAP block is to deposit local anaesthetic in the plane between the internal oblique and transversus abdominis muscles targeting the spinal nerves in this plane. Sensory innervation to the abdominal wall skin and muscles up to the parietal peritoneum will be interrupted. If surgery extends beyond the parietal

peritoneal, dull visceral pain (from spasm or inflammation following surgical insult) will still be experienced.

The block can be performed blind or using the ultrasound.

BLIND TAP

The point of entry for the blind TAP block is the lumbar triangle of Petit. This is situated between the lower costal margin and iliac crest. It is bound anteriorly by the external oblique muscle and posteriorly by the latissimus dorsi. This technique relies on feeling double pops as the needle traverses the external oblique and internal oblique muscles. A blunt needle will make the loss of resistance more appreciable.

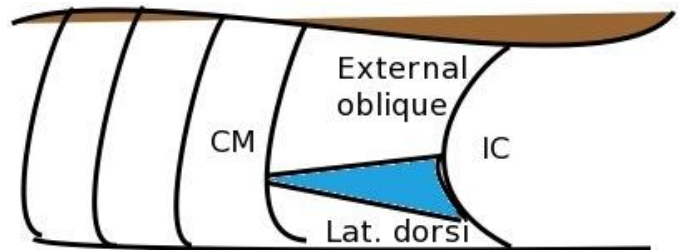
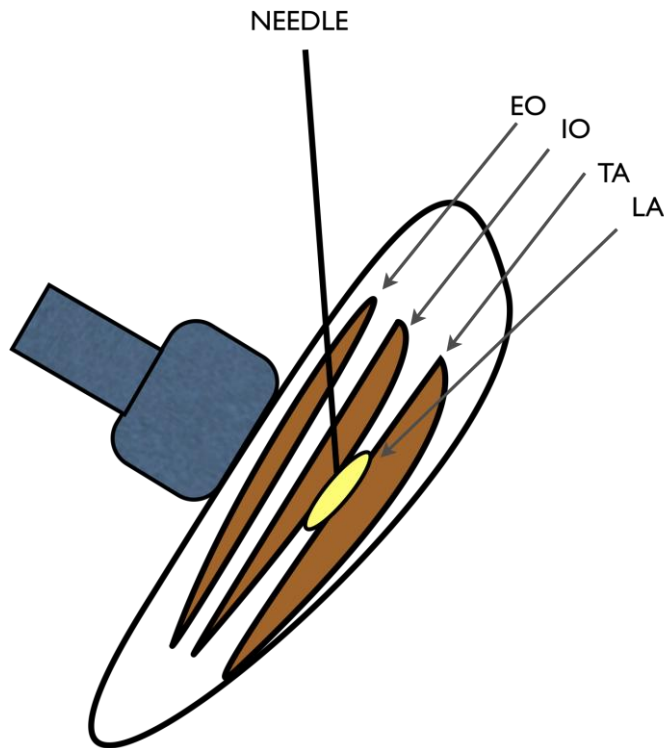


Figure 3. Lumbar triangle of Petit between external oblique muscle and latissimus dorsi.

CM: costal margin, IC: iliac crest.

ULTRASOUND GUIDED TAP

The ultrasound probe is placed in a transverse plane to the lateral abdominal wall in the midaxillary line, between the lower costal margin and iliac crest. The use of ultrasound allows for accurate deposition of the local anaesthetic in the correct neurovascular plane.



Needle: 50 mm or 80 mm needle
20ml needle and injection tubing
20 to 30 ml local anaesthetic (any local anaesthetic concentration, this block relies on local anaesthetic spread rather than concentration, i.e. volume dependant.)

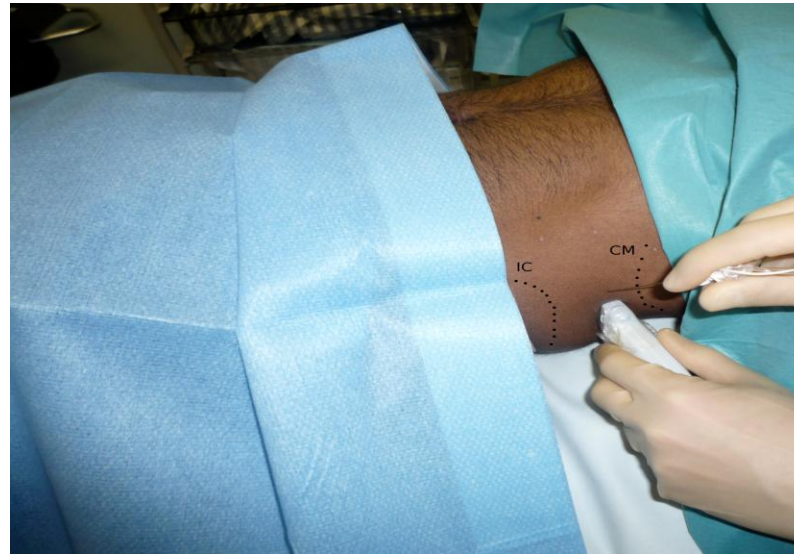


Figure 4. Schematic view of an ultrasound-guided transversus abdominis plane block. EO: external oblique, IO: internal oblique, TA: transversus abdominis, LA: local anaesthetic

Whilst the patient is in the supine position, a high frequency ultrasound probe is placed transverse to the abdominal wall between the costal margin and iliac crest. The image produced shows (from above downwards) skin, subcutaneous fat, external oblique, internal oblique, transversus abdominis. The peritoneum and underlying organs are visualized deeper to the muscles.

If prolonged analgesia is required beyond the duration of a single shot of local anaesthetic, a catheter can be introduced into the transversus abdominis plane through a Touhy needle. After opening up the plane with 2 ml of saline, the catheter is introduced around 3 cm beyond the needle tip. Position is verified by injecting the local anaesthetic bolus (20ml). An infusion of a dilute local anaesthetic is started at a rate of 7 to 10 ml per hour.

PERFORMING THE ULTRASOUND GUIDED BLOCK

REQUIREMENTS

- Ultrasound machine with a high frequency probe (eg.13-6 MHz)
- Ultrasound probe cover
- Antiseptic for skin disinfection
- Sterile ultrasound gel

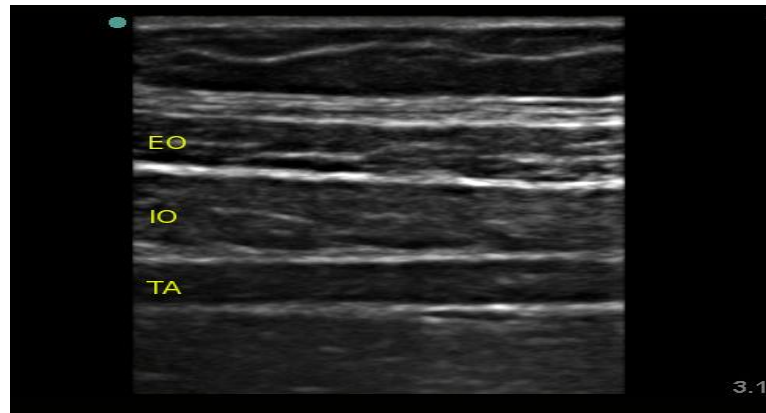


Figure 5. Image of the abdominal wall. EO: external oblique, IO: internal oblique, TA: transversus abdominis

The needle is introduced in plane of the ultrasound probe directly under the probe and advanced until it reaches the plane between the internal oblique and transversus abdominis muscles. The needle can also be

introduced a few centimeters medial to the probe (a distance equivalent to the depth of the plane as viewed on the ultrasound image). The probe will have to follow the needle entry point medially in its superficial path and is then returned to its original position in the midaxillary line as the needle is directed deeper.

Upon reaching the plane, 2 ml of saline is injected to confirm correct needle position after which 20 ml of local anaesthetic solution is injected. The transversus abdominis plane is visualized expanding with the injection (appears as a hypoechoic space).

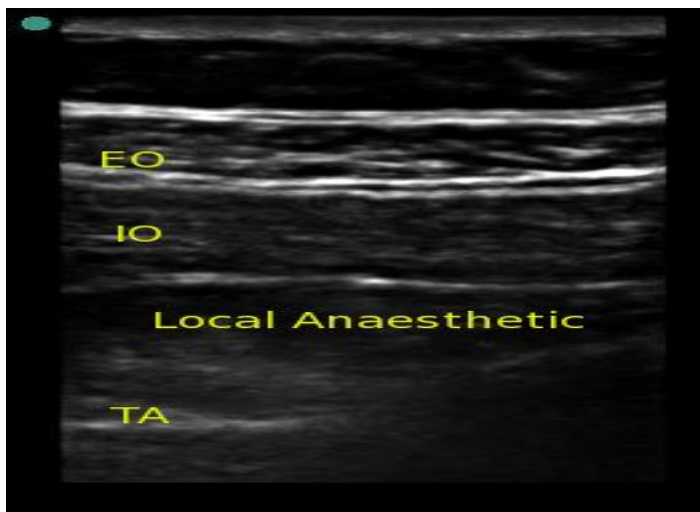


Figure 6. Correct local anaesthetic deposition in the transversus abdominis plane.

INDICATIONS

This block is indicated for any lower abdominal surgery including appendectomy (4), hernia repair, caesarean section (5), abdominal hysterectomy (6) and prostatectomy (7). Efficacy in laparoscopic surgery and renal transplantation has also been demonstrated (8,9,10). Bilateral blocks can be given for midline incisions or laparoscopic surgery. Care should be taken not to exceed recommended safe doses of local anaesthetic agent with bilateral injections.

There has been controversy in the literature regarding the spread and level of block achieved with a single TAP injection. Whilst early studies showed a T7 to

L1 spread with a single posterior injection making the block suitable for midline abdominal incisions (11), other studies failed to demonstrate a spread cephalad to T10 making it more suited for lower abdominal surgery (12).

In a small cadaveric study, T11, T12 and L1 were most consistently present in the transversus abdominis plane, while T10 was present in 50% of the cases (13). It is reasonable to expect a good analgesic effect in the region between T10 and L1 following a single posterior injection. Augmentation with a subcostal injection will help attain a higher block up to T7. The subcostal TAP is a modification of the original technique in which the ultrasound probe is placed just beneath the costal margin and parallel to it. The needle is then introduced from the lateral side of the rectus muscle in plane of the ultrasound beam and 10 ml of local injected into the transversus abdominis plane to extend the analgesia provided by the posterior TAP block above the umbilicus (14).

COMPLICATIONS

There have been very few reports of complications with TAP blocks. Most of the reported complications occurred with the blind technique, which is expected because the appreciation of the “pops” as the needle traverses the different fascial planes between the abdominal muscles may be difficult. Landmarks in obese patients may also be challenging (15). The most significant complication was a case report of intrahepatic injection in a patient with an enlarged liver (16). There was also a reported case of intraperitoneal continuous TAP catheter placement without abdominal organ damage.(17) Other potential complications include: intraperitoneal injection, bowel hematoma and transient femoral nerve palsy. The latter may occur as the fascia iliaca is continuous with the transversalis fascia. Local anaesthetic toxicity remains a possibility due to the large volumes required to perform this block especially if it was done bilaterally. As with any regional technique, careful aspiration will help avoid intravascular injections.

The use of ultrasound-guided TAP block has gained substantial popularity recently, which will inevitably lead to a rise in the reported complications. One case of liver laceration during ultrasound-guided TAP block performance has been reported (18). This was due to a combination of poor ultrasound machine choice and an operator error. It has to be emphasized that the success of

a TAP block depends on the correct deposition of local anaesthetic in the plane between the internal oblique and transversus abdominis plane. This necessitates real-time visualization of the block needle as it is advanced in-plane of the ultrasound beam which requires operator experience and manual dexterity as the ultrasound probe may have to be repeatedly tilted to allow adequate needle view. Ultrasound usage may only enhance safety if used safely.

REFERENCES

1. Rafi A. Abdominal field block: a new approach via the lumbar triangle. *Anaesthesia* 2001; **56**: 1024-26.
2. Hebbard P, Fujiwara Y, Shibata Y, Royse C. Ultrasound-guided transversus abdominis plane (TAP) block. *Anaesth Intensive Care* 2007; **35**: 616-7.
3. Gray H. Anatomy of human the body. 12th edition. New York. *Bartleby.com*; 2000: 211-12
4. Niraj G, Searle A, Mathews M, et al. Analgesic efficacy of ultrasound-guided transversus abdominis plane block in patients undergoing open appendectomy.. *Br J Anaesth* 2009 103(4): 601-605
5. McDonnell JG, Curley G, Carney J, et al. The analgesic efficacy of transversus abdominis plane block after cesarean delivery: a randomized controlled trial. *Anesth Analg* 2008; 106:186-91
6. Carney J, McDonnell JG, Ochana A, et al. The transversus abdominis plane block provides effective postoperative analgesia in patients undergoing total abdominal hysterectomy. *Anesth Analg* 2008; 107:2056-60
7. O'Donnell BD, McDonnell JG, McShane AJ. The transversus abdominis plane (TAP) block in open retropubic prostatectomy. *Reg Anesth Pain Med* 2006; 31:91
8. Mukhtar K, Singh S. Transversus abdominis plane block for laparoscopic surgery. *Br J Anaesth* 2009; 102(1): 143-4
9. El-Dawlatly A, Turkistani A, Kettner S, et al. Ultrasound-guided transversus abdominis plane block: description of a new technique and comparison with conventional systemic analgesia during laparoscopic cholecystectomy. *Br J Anaesth* 2009 102(6): 763-767
10. Mukhtar K, Khattak I. Transversus abdominis plane block for renal transplant recipients. *Br J Anaesth* 2010 104: 663-664
11. McDonnell J, Laffey J. Transversus Abdominis Plane Block. *Anesth Analg* 2007; **105**: 883.
12. Shibata Y, Sato Y, Fujiwara Y, Komatsu T. Transversus Abdominis Plane Block. *Anesth Analg* 2007; **105**: 883.
13. Tran TMN, Ivanusic JJ, Hebbard P, et al. Determination of spread of injectate after ultrasound-guided transversus abdominis plane block: a cadaveric study. *Br J Anaesth* 2009; **102**(1): 123-7
14. Hebbard P. Transversus abdominis plane (TAP) block. 2007; Website: www.heartweb.com.au/downloads/TAPblock.pdf
15. Bonnet F, Berger J, Aveline C. Transversus abdominis plane block: what is its role in postoperative analgesia. *Br J Anaesth* 2009 103(4): 468-470
16. Farooq M, Carey M. A Case of Liver Trauma With a Blunt Regional Anesthesia Needle While Performing Transversus Abdominis Plane Block *Reg Anesth Pain Med* 2008; **33**: 274-5.
17. Jankovic Z, Ahmad N, Ravishankar N, et al. Transversus Abdominis Plane Block: How Safe is it? *Anesth Analg* 2008; 107:1758-1759
18. Lancaster P, Chadwick M. Liver trauma secondary to ultrasound-guided transversus abdominis plane block. *Br J Anaesth* 2010 104:510-511