

# Sciatic Nerve Block (Anterior Approach using Neurostimulation without Ultrasound Guidance)

By Arthur Atchabahian, MD  
Assistant Professor of Anesthesiology  
Director of Regional and Orthopedic Anesthesia

*St Vincent Catholic Medical Center, New York City, NY*

The anterior approach to sciatic nerve blockade in the inguinal area can be performed on a supine patient, thus obviating the need for repositioning, e.g. in case of trauma. That advantage is also provided by the lateral approach to sciatic nerve block and the lateral popliteal block. Another benefit is that a femoral nerve block can be performed using the same skin preparation.

*The Journal of NYSORA 2009; 12: 24-27*

## SCIATIC NERVE BLOCK (ANTERIOR APPROACH)

### INTRODUCTION

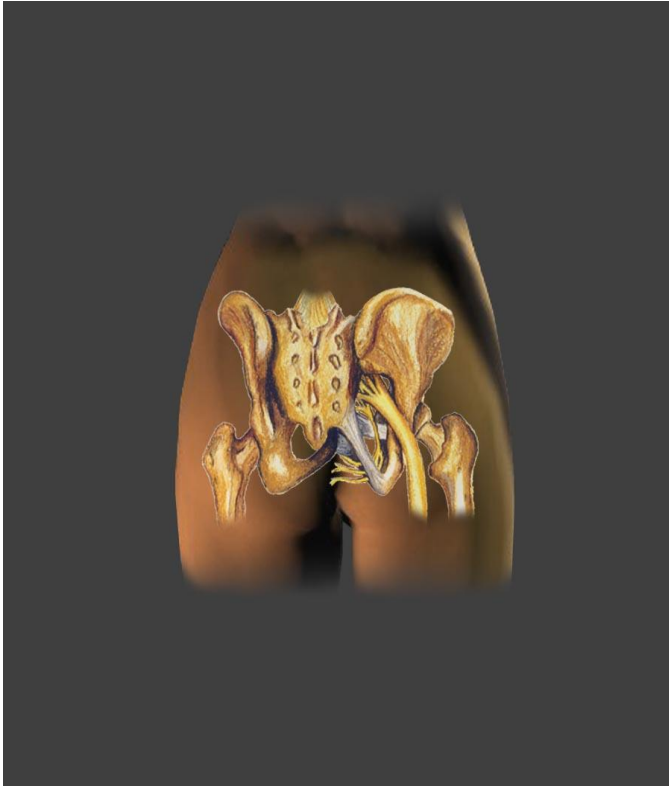
The anterior approach to sciatic nerve blockade in the inguinal area can be performed on a supine patient, thus obviating the need for repositioning, e.g. in case of trauma. That advantage is also provided by the lateral approach to sciatic nerve block and the lateral popliteal block. Another benefit is that a femoral nerve block can be performed using the same skin preparation.

This approach was initially described by Beck in 1963 (1). Chelly (2) described a similar approach, based on somewhat different landmarks. However, the resulting insertion point is usually more or less the same. More recently, Souron and Delaunay (3) described an approach based exclusively on surface landmarks, usually resulting in a slightly more distal needle insertion point.

Compared to the classic approach (Labat) or the parasacral approach, the anterior approach has three main theoretical disadvantages:

- 1) The needle crosses more tissue and muscle planes. Thus, the procedure might be more painful for the patient, and more sedation/analgesia may be needed to perform it.
- 2) The block is more distal, and there is a theoretical risk of not blocking the posterior cutaneous nerve of the thigh (PCNT), with consequently no anesthesia of the posterior aspect of the thigh. A thigh tourniquet would then be poorly tolerated.
- 3) The superficial and deep femoral vessels, as well as branches of the femoral nerve, lie anterior and medial to the femoral shaft, and there is a theoretical risk of injuring them during the block performance. To our knowledge, no such incident has been described.

This block is relatively contra-indicated in patients who had vascular surgery in the groin area (as ultrasound guidance is not used), and in coagulopathic patients.

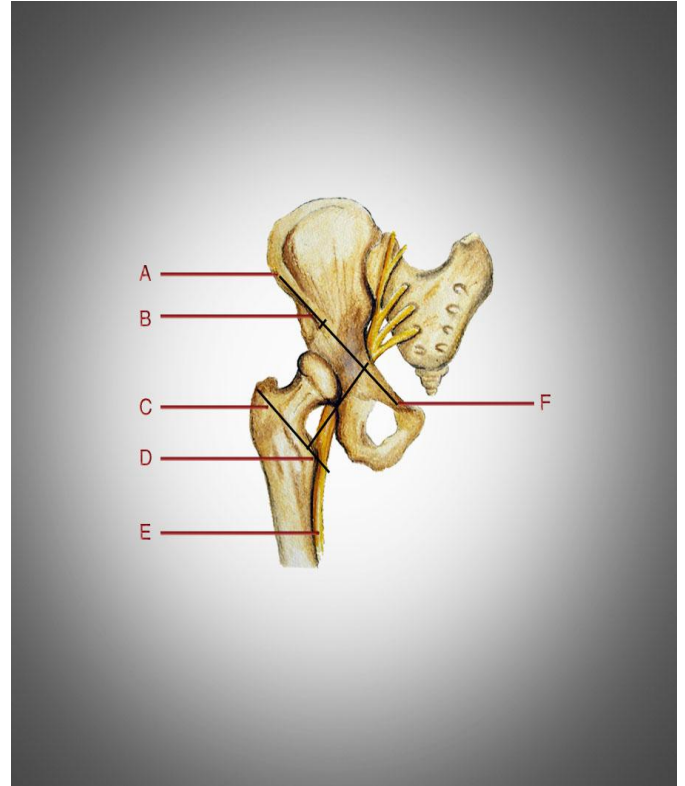


**Figure 1.** Anatomy of the sciatic nerve (posterior view).

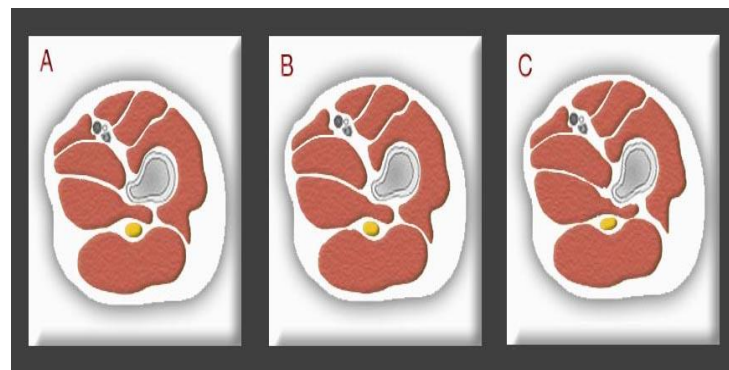
### ANATOMY

The sciatic nerve, terminal branch of the sacral plexus that exits the pelvis through the greater sciatic notch, has initially a curved route before becoming more or less parallel to the femoral shaft at the thigh (Figure 1). In this technique, the sciatic nerve is blocked while posterior and medial to the lesser trochanter, or to the femoral shaft immediately distal to the lesser trochanter. Anatomic variations are common, and the nerve may be more or less medial to the femur. The landmarks described by Beck aim at locating the lesser trochanter based on the position of the greater trochanter, which is palpated at the lateral aspect of the upper thigh (Figure 2).

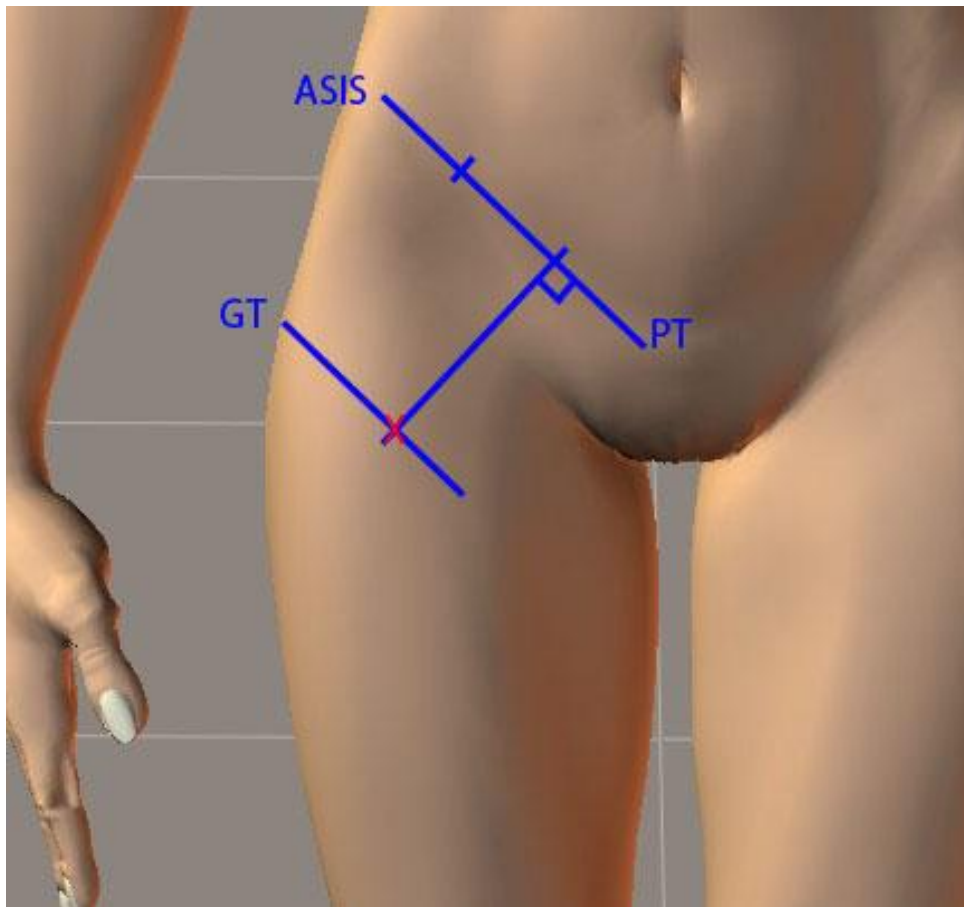
Common sense would suggest that external rotation of the lower extremity, by bringing the sciatic nerve in a more medial position, would make the block easier to perform. Clinical and MRI studies (4, 5) suggest that that advantage is at best minimal, and that a better access to the nerve is actually provided by internal rotation, which gets the lesser trochanter "out of the way" by rotating it towards posteriorly (Figure 3).



**Figure 2.** The landmarks described by Beck aim at locating the lesser trochanter. A) Anterior superior iliac spine (ASIS); B) Line joining the ASIS and the pubic tubercle (F); C) Greater trochanter; D) Lesser trochanter; E) Sciatic nerve; F) Pubic tubercle.



**Figure 3.** Illustration of MRI cross-sections of the left leg of a male volunteer (adapted from Moore et al.) in external rotation (A), neutral position (B) and internal rotation (C). Internal rotation displaces the lesser trochanter from the line of sight, thus facilitating needle passage.



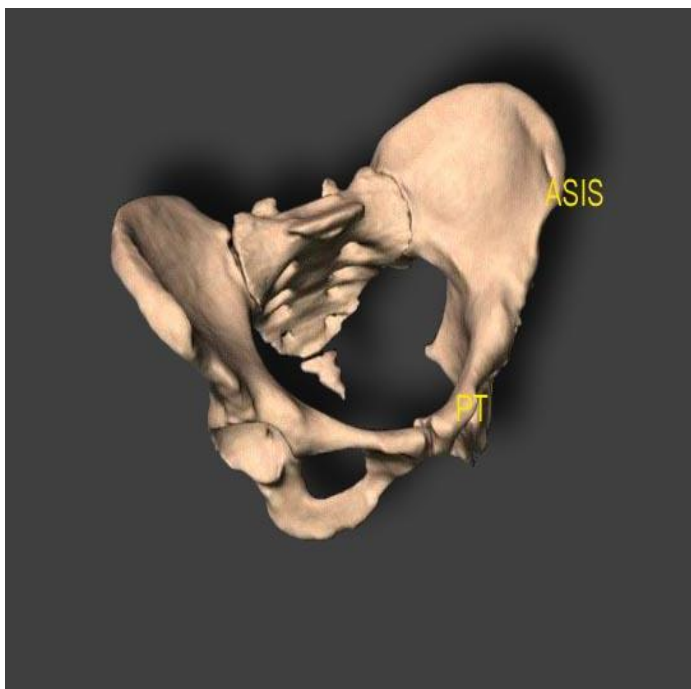
**Figure 4.** Landmarks for the anterior approach to sciatic nerve blockade following the approach described by Beck.  
**ASIS:** Anterior-superior iliac spine; **PT:** Pubic tubercle; **GT:** Greater trochanter; **X:** Needle insertion point.

### TECHNIQUE

The patient is placed supine. The upper body is best positioned flat, especially in obese patients, in order to minimize folds in the inguinal area. The three following bony landmarks are identified (Figure 4):

- 1) The anterior superior iliac spine (ASIS), which is located by following the iliac crest anteriorly, up to the point where the bone edge more or less abruptly changes orientation and gets directed caudally (Figure 5)
- 2) The pubic tubercle (PT), which is found first by palpating the pubic bone in the lower abdomen, then rolling the fingers laterally from the median symphysis. The bony bulges felt on each side are the pubic tubercles.
- 3) The greater trochanter (GT), specifically its proximal edge, easily felt (except in morbidly obese patients) at the lateral aspect of the upper thigh.

Using a skin marker, a line (A) is drawn between ASIS and PT, representing the inguinal ligament. This line is then divided into three thirds. A second line (B) parallel to A is drawn through the proximal pole of the GT. A third line (C), perpendicular to both A and B, and crossing A at the junction between medial third and lateral two-thirds, is drawn. The intersection between B and C, point D, is the needle insertion point.



**Figure 5.** Position of the pelvic bony landmarks.  
**ASIS:** anterior superior iliac spine; **PT:** pubic tubercle.

### TECHNIQUE (CONTINUED...)

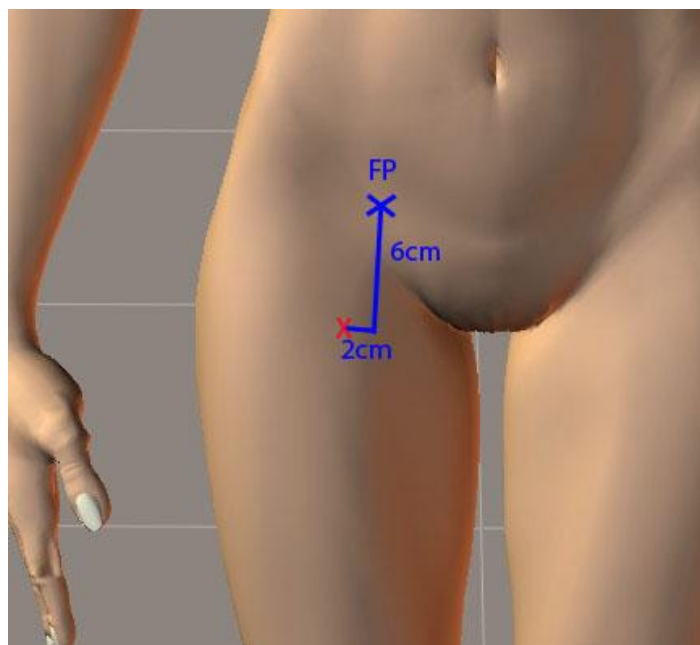
After local anesthesia of the skin and underlying tissues with 1% lidocaine, a 12- or 15-cm stimulating needle is inserted perpendicular to the floor, like a plumb-bob. The nerve stimulator is set to deliver a current between 1.2 and 1.5 mA. Initially, twitches in the quadriceps are commonly seen, as the muscle is crossed. Some authors recommend decreasing the current when quadriceps contractions are seen, and redirecting the needle if contractions persist at a current < 0.5 mA, to avoid injuring branches of the femoral nerve. Redirecting in case of paresthesia is probably sufficient.

Typically, the lesser trochanter will be encountered at a variable depth, depending on patient habitus. For an average-sized patient, this depth is around 7 or 8 cm. The needle should then be withdrawn 1-2 cm, and walked medially until bone contact is lost. The sciatic nerve will then be encountered 2-3 cm deeper than bone depth, i.e. at 9-12 cm from the skin. Sometimes, the nerve is stimulated without having contacted bone. A response

distal to the knee, either in the tibial or peroneal innervation territory, is acceptable. Needle position is adjusted as the current is decreased, and a current  $\leq 0.4$  mA is accepted. The chosen local anesthetic (0.5% ropivacaine, 2% lidocaine, 1.5% mepivacaine, or 2 or 3% 2-chloroprocaine) is then injected slowly, in a fractionated fashion, with frequent aspiration. In our experience, 20 mL is usually sufficient to block all three components of the sciatic nerve, i.e. peroneal, tibial and posterior cutaneous of the thigh nerves. Always aspirate after injecting about 1 mL, as the needle might be obstructed by tissue, and it is better to diagnose an intravascular position of the needle tip after 1 rather than 5 mL of local anesthetic have been injected.

Because of the large size of the sciatic nerve, 25-40 minutes may be necessary for full blockade.

Alternative landmarks have been developed by Souron and Delaunay (Figure 6). The insertion point is usually slightly more distal and medial than with the previous technique, but the performance of the block is similar. The main advantage lies in the lack of need for complicated Euclidian geometry.



**Figure 6.** Alternative landmarks developed by Souron and Delaunay (3). The femoral pulse (**FP**) is palpated in the inguinal crease. The needle insertion point (**X**) is 6 cm distal (in the axis of the limb) and 2 cm lateral.

A very similar approach has been described by Wiegel et al. (6) The needle insertion point is described as "5 cm distal from the insertion point of the femoral block".

Van Elstraete et al. described another approach, which has the advantage of a more distal and medial entry point, allowing reaching the sciatic nerve even when it is posterior to the femur. However, it is not clear whether the success rate is higher than when the other methods are used.

prolonged block from a neuropathy due to the surgery. In order to shorten the block duration, it is then preferable to use a mixture of bupivacaine or ropivacaine with a shorter-acting agent, e.g. by mixing 1:1 0.5% ropivacaine and 2% mepivacaine, for a duration of 14-16 hours.

## PEARLS AND TRICKS

1) In some cases, no motor response is obtained. My approach when this happens is:

-First, to change the needle angle in a transverse plane, more medially or more laterally (as long as bone is not encountered);

-Then, to rotate the lower extremity, first internally, then externally;

- If this fails, my experience suggests that the needle may need to be directed slightly more distally, in order to reach the sciatic nerve below the lesser trochanter. I do not recommend angling the needle more proximally, as the hip joint capsule, which inserts on the intertrochanteric line, could then be entered.

2) If the hamstring muscles are stimulated, but that no response distal to the knee can be obtained, it is best to use a different approach. However, if a response below the knee is obtained at a relatively high current, but cannot be maintained at a low current, while the hamstring response persists, our experience suggests that this can be accepted as a last resort. A satisfactory block was obtained each time in our limited experience. However, as in any nerve block when a proximal response is accepted, there is a risk that only a side branch to the hamstrings will be blocked, leaving the lower leg sensation and power intact.

3) If bupivacaine or ropivacaine is used, the block may last over 24 hours, especially in older patients. After a total hip or knee arthroplasty, it may be difficult to differentiate a

## REFERENCES

1. Beck GP. Anterior approach to sciatic nerve block. *Anesthesiology* 1963;24:222-224 ([Pubmed](#))
2. Chelly JE, Delaunay L. A new anterior approach to the sciatic nerve block. *Anesthesiology* 1999;91:1655-1660 ([Pubmed](#))
3. Souron V, Delaunay L. Nouveaux repères du bloc sciatique par voie antérieure: étude préliminaire. *Ann Fr Anesth Réanim* 2001;20 (suppl):R186
4. Moore CS, Sheppard D, Wildsmith JA. Thigh rotation and the anterior approach to the sciatic nerve: a magnetic resonance imaging study. *Reg Anesth Pain Med* 2004;29:32-35 ([Pubmed](#))
5. Vloka JD, Hadzic A, April E, Thys DM. Anterior approach to the sciatic nerve block: the effects of leg rotation. *Anesth Analg* 2001;92:460-462 ([Pubmed](#))
6. Wiegel M, Reske A, Hennebach R, Schmidt F, Elias T, Gupta H, Olthoff D. Anterior sciatic nerve block – new landmarks and clinical experience. *Acta Anaesthesiol Scand* 2005; 49:552-557 ([Pubmed](#))