

LOWER EXTREMITY NERVE BLOCKS IN PEDIATRIC PATIENTS

BY DALENS B

Pediatric applications of plexus and conduction nerve blocks have increased considerably in recent years, and they have indications in virtually all aspects of surgical and procedural pain, including outpatient surgery, whether the techniques are used in conscious patients or in combination with general anesthesia. Lower extremity nerve blocks remain underutilized despite their many advantages in terms of efficacy, safety and ease with which they can be performed with the help of a nerve stimulator. A major improvement in recent years consisted in the development of techniques allowing catheter placement for continuous infusion of local anesthetics.

INTRODUCTION

In recent years, pediatric applications of plexus and conduction nerve blocks have increased considerably and they have indications in virtually all aspects of surgical and procedural pain, including outpatient surgery, whether the techniques are used in conscious patients or in combination with general anesthesia.[1] Peripheral nerve blocks remain underutilized despite their unique ability to provide localized analgesia with small amounts of local anesthetics (LA). Two recent discoveries still reinforce this interest, especially for lower extremity nerve blocks: 1) sensitization of the peripheral nervous system plays a major role in sustaining postoperative pain and can be effectively prevented by conduction nerve blockade and not by opioid analgesia which is only effective on central sensitization whereas; 2) when discontinued, opioids exhibit pronociceptive effects which correlate with the doses and duration of treatment.[2,4] Consequently, there has been a resurgence of an interest in the use of peripheral nerve blocks for management of postoperative pain, particularly now since the limitation of single-shot blockade (i.e., limited duration of analgesia), can be overcome with placement of catheters along nerve paths. It is likely that the use of both single-shot and continuous peripheral nerve blocks will significantly increase in the future as the quest for decreasing the psychological stress of surgery and overall costs of hospitalization continues.

RATIONALE

SURGICAL PAIN COMPONENTS

Postoperative pain is multifactorial and results from several conditions including: 1) skin and muscle trauma, trauma to the fascias, periosteum and bones (somatic pain); 2) ischemia of mesenteric vessels and traction of peritoneum (visceral pain); 3) local inflammatory disorders and spinal reflexes (inflammation and neural plasticity); and 4) joint mobilizations, wound dressings, venepunctures and other types of procedural pain.

Postoperative pain depends both on central sensitization [5,6] and an input from the periphery (tissue trauma).[7,8] Prevention and treatment of the persistent pain should focus on targeting both central sensitization (e.g., opioids), as well as active peripheral nerve nociceptive input. The latter goal at present can be reliably achieved only by interrupting the transmission from the peripheral nerve fibers supplying the injured area. Of note, while parenteral opioids and regional blocks techniques are equally effective on postoperative pain at rest, only regional blocks can 1) suppress pain on mobilization of patients and procedural pain, and 2) prevent inflammatory disorders and neural plasticity.[9]

SELECTION OF THE ANALGESIC MODALITIES FOR POST-OPERATIVE ANALGESIA

Although perception of pain is highly variable among patients, it is possible to estimate the intensity and

duration of postoperative pain in most patients and elective surgery scenarios. There are three main commonly encountered scenarios in clinical practice: outpatient surgery, elective surgery on hospitalized patients and emergency procedures.

Outpatient surgery often requires "minimally" invasive anesthesia, i.e., anesthetic techniques with short-acting intravenous or inhalational anesthetics, which results in short-lived and substandard postoperative analgesia at home in a significant proportion of patients.[10-12] When applicable, a regional block with LA with or without the addition of an adjuvant (e.g., clonidine) is the most effective choice. Both intraoperative and

documented, preferably in the presence of a witness and/or by a neurologist, before the performance of the nerve block procedure.

PRINCIPLES OF SELECTION OF A LOWER EXTREMITY NERVE BLOCK

For many surgical procedures, a single shot nerve block is appropriate both in terms of duration of analgesia and morbidity.[15-17] The most commonly used local anesthetics are displayed in **Table 1**. Most single shot lower extremity nerve blocks procedures are also applicable to day case surgery patients. Partial motor blockade does not prevent hospital discharge provided that

Table 1

Local anesthetic	Usual concentration (%)	Usual doses (mg/kg)	Maximum dose ^a (mg/kg)	Maximum ^a dose with epinephrine (mg/kg)	Latency (min)	Duration of effects (h)
Lidocaine	0.5-2	Up to 5	7.5	10	5-15	0.75-2
Mepivacaine	0.5-1.5	Up to 7	8	10	5-15	1-1.25
Bupivacaine	0.25-0.5	Up to 2	2.5	3	15-30	2.5-6 ^b
Ropivacaine	0.2-1	Up to 3	3.5	Not used	5-12	2.5-4 ^b
Levobupivacaine	0.25-0.5	Up to 3.5	4	4	15-30	2.5-6 ^b

a: Maximum doses are hypothetical and subjective; toxicity results from peak plasma concentration of the free unbound form, not from the total dose injected; the maximum doses mentioned in this table are safe when given as single injections, whereas they might be or might not be safe following multiple previous injections (or continuous infusion), especially with long-lasting local anesthetics (bupivacaine and probably too, ropivacaine and levobupivacaine).

b: May last more than 12, even 18, hours following certain block procedures (sciatic nerve block especially).

postoperative analgesia is ensured by the same technique, in most cases allowing for administration of light general anesthesia.

Hospitalized patients more commonly undergo more extensive surgical procedures that usually require long lasting techniques of analgesia. If the patients are only exposed to pain at rest, regional anesthetic techniques and administration of parenteral opioids (PCA especially) are similarly effective (13,14). However, if pain at mobilization (especially following orthopedic procedures) or procedural pain (wound dressings, mobilization of drainages) is expected, analgesia achieved with regional blocks is far superior to that achieved with parenteral narcotics.

Emergency procedures: Patients requiring emergency procedures and/or those whose physical status is not stabilized require special attention. Whenever applicable, peripheral nerve blocks are preferred because they do not change the level of consciousness or affect the hemodynamic stability. However, precautions must be taken as there may be legal implications in case of neurological lesions that were not fully evaluated and/or

the parents are insightful and well informed, although the ambulation may not be possible. However, if there is a potential risk of developing a compartment syndrome, it would be preferable to monitor the patient adequately on the ward and delay hospital discharge until complete recovery, or avoid the nerve blocks altogether.

Because the attachment of perineural sheaths to the underlying structures is loose, the LA can occasionally reach distant nerves or anatomical spaces (e.g. an epidural, even a subarachnoid block may result from a posterior approach to the lumbar plexus) and cause complications unexpected by those unaware of this possible effect. Such a possibility must be considered when selecting a block procedure. Special precautions must be taken with agitated children to avoid postoperative trauma in anesthetized areas. Careful monitoring of the anesthetized extremity must be performed hourly to prevent the development of a compartment syndrome. This hourly evaluation includes monitoring of the hemodynamic status, the local temperature and re-coloration time of the limb, the mobility of the toes or fingers and increasing numbness and/or paresthesia.

After surgery resulting in a more significant tissue trauma, analgesia of adequate duration cannot be achieved with a single shot block, even when a long-acting local anesthetic is used. Concomitant administration of adjuvants, such as clonidine (1-2 µg/kg) may extend the duration of analgesia [18,19] without precluding hospital discharge. However, when long lasting pain relief is mandatory, placement of an indwelling catheter in the vicinity of the nerve or within a fascial compartment traversed by the nerve to be blocked are the most suitable and effective alternatives. These techniques are however relatively new in pediatric practice and the scientific data documenting our clinical impression is not available yet in the literature.[20,21] While continuous nerve block techniques are currently widely used in inpatients, there is a trend toward extending their use also in outpatient population. The indications for these techniques must take into consideration the agitated or difficult child and the patients at risk of developing a compartment syndrome, particularly in patients receiving a cast.[22-24]

INDICATIONS

ANATOMIC CONSIDERATIONS

Sensory and motor supply to the lower extremity is more elaborate than that of the upper extremity and involves two separate plexii (lumbar and sacral).

ORGANIZATION OF THE LUMBAR AND SACRAL PLEXII

The lumbar plexus is formed by the union of the first four lumbar spinal nerves which reunite within the substance of the psoas major muscle, in a fascial plane termed the "psoas compartment" where it can be approached via a posterior route through the quadratus lumborum muscle. It supplies four nerves to the anterior part of the lower extremity, the femoral, lateral cutaneous, obturator and genitofemoral nerves. The psoas and iliacus muscles are enveloped by the same aponeurosis, the fascia iliaca sheath. At their emergence from the psoas muscle, all lumbar plexus nerves run a variable part of their course just below this fascia. Consequently, an injection of adequate volume of local anesthetic within the inner surface of this fascia will result in blockade of the plexus components enveloped by the iliaca sheath. This is the anatomical concept behind the technique of the fascia iliaca compartment block.

The femoral nerve is the main branch of the lumbar plexus. It emerges from the psoas major muscle in the groove separating the psoas and the iliacus muscles, passes behind the inguinal ligament and enters the groin in the femoral triangle (Scarpa's triangle), lateral to the femoral vessels from which it remains separated by the lower part of the psoas major muscle. Of note, the femoral nerve does not enter the perivascular sheath, contrary to the brachial plexus which is contained in the perivascular sheath in the axilla. The main division branch of the femoral nerve is the saphenous nerve, a purely sensory nerve which continues the general direction of the femoral nerve, lateral to the femoral artery in the adductor canal (Hunter's canal) accompanied by the motor branch supplying the vastus medialis muscle. Due to this close relationship, injection of local anesthetic after stimulation of the branch to the vastus medialis invariably results in saphenous nerve block. The saphenous nerve then crosses the femoral vessels anteriorly, passes behind the sartorius muscle, descends along the medial border of the tibia and divides into terminal branches at the level of the medial malleolus. The saphenous nerve supplies the skin of the medial part of the leg and foot.

SACRAL PLEXUS AND SCIATIC NERVE

The sacral plexus is formed by the union of the fifth lumbar with the first four sacral spinal nerves. It lies on the anterior aspect of the piriformis muscle, behind the posterior wall of the pelvic cavity and cannot be approached percutaneously. It supplies the posterior aspect of the upper limb and almost entire limb below the knee (except for the medial strip of skin, supplied by the saphenous nerve). Its two main divisions supplying the lower extremity are the posterior femoral cutaneous nerve and the sciatic nerve. The sciatic nerve is the largest mixed nerve of the body. It is formed by two distinct nerves within the same envelope, the common peroneal nerve and the tibial nerve. The sciatic nerve leaves the pelvis through the greater sciatic foramen, enters the thigh between the greater trochanter of the femur and the ischial tuberosity, then runs in the subgluteal space within a "true" aponeurotic canal wherein the pressure is negative and can be detected by a loss-of-resistance technique. It is separated from the hip joint by the obturator externus muscle. In the thigh, the sciatic nerve runs on the adductor magnus, along the lower border of the femur, in direction to the popliteal fossa where its two constitutive nerves separate.[25] The tibial nerve continues the general

direction of the sciatic nerve and supplies the dorsal aspect of the leg and the plantar surface of the foot. Whilst the common peroneal reaches the lateral aspect of the leg and the dorsum of the foot.

BLOCK OF THE COMPONENTS OF THE LUMBAR PLEXUS

Femoral nerve blocks are perhaps the most commonly performed lower limb blocks in pediatric patients. This technique is of particular interest in children with a fractured shaft of the femur. The block should be performed as early as possible after the accident in order to improve the comfort of the child during transport, allow pain-free physical and radiological examinations, wound dressings and orthopedic procedures, and reduce the bleeding. Femoral nerve block is also recommended for pain relief in elective operations on the thigh (surgeries involving soft tissues as well as orthopedic procedures) provided the territory supplied by the lateral cutaneous nerve is anesthetized (a fascia iliaca compartment block is particularly suitable for achieving this goal). For brief, minor procedures such as a muscle biopsy of the thigh, children tolerate well both the block procedure and the surgery with minimal intravenous sedation.[26] Placement of a catheter allows long-lasting pain relief following femoral fractures [27,28]; this technique has a high degree of patient's satisfaction in adults, especially with patient-controlled techniques.[29] However, high rate of 57% rate of bacterial contamination of the site of insertion (without actual infections) was reported to occur 48h after catheter placement; thus strict antiseptic precautions must be followed.[30]

Lumbar plexus blocks have limited indications in pediatric patients and may be considered when a femoral block is contraindicated (infection at the site of puncture) or unsuitable (when sensory supply has a sciatic nerve component as for hip surgery). They may also represent a valuable alternative to epidural anesthesia for unilateral operations on the hip and thigh the more so as they allow easy catheter placement for long-lasting pain relief.[31]

The saphenous nerve block is mainly used to complement a sciatic nerve block for procedures below the knee or on the foot. Due to the small doses and volumes of LA that are required, this block does not significantly increase the risks of systemic toxicity.

Other block procedures of lumbar plexus nerves are little used in children. A lateral cutaneous nerve block can be used for muscle biopsy [26] and surgery of the soft tissues in the lateral aspect of the thigh but most

anesthesiologists would prefer using a fascia iliaca compartment block or a three-in-one block in this indication. Obturator nerve blocks have virtually no specific anesthetic indications; they might be suitable to facilitate rehabilitation of children with a history of spasticity but the benefits are short-lasting and its safety profile is dubious. For that reason, most anesthesiologists would prefer performing a lumbar plexus block or an epidural anesthesia with placement of a catheter for repeat, continuous or on-demand injections of LA.

SACRAL PLEXUS NERVE BLOCKS

Sciatic nerve blocks are recommended for operations on the foot (especially clubfoot) and the leg. A complementary block of the saphenous or femoral nerve is often necessary to anesthetize the skin of the medial part of the leg. Due to the simplicity of the technique and distal location, the popliteal approach to the sciatic nerve should always be considered first.[15,32] Proximal approaches are selected only when surgery of the knee is planned (which is unusual in pediatric patients) or when the posterior femoral cutaneous nerve should be simultaneously blocked (a proximal approach to the sciatic nerve almost always results in complete blockade of this nerve, even though it runs in an apparently separate fascial tunnel).

CONTRAINDICATIONS

There are only a few true contraindications to lower extremity nerve blocks.[1,17] They may include infection at the puncture site and true allergy to local anesthetics (a very rare condition, especially with aminoamides). Bleeding disorders or anticoagulant therapy are relative contra-indications and apply mainly for deep block procedures and perhaps insertion of indwelling catheters.

Degenerative axonal diseases have long been considered as contraindications to any regional anesthesia. However, there are no data to support the hypothesis that a conduction block could aggravate the disease, or data suggesting to the contrary. Regardless, it may be preferable to avoid regional procedure in these patients unless a clear indication has been established, written informed consent obtained and a complete and well documented neurological examination is performed. If adequate monitoring of patients at risk of compartment

syndrome cannot be guaranteed, performing a regional block would be imprudent and should be avoided. Obviously, parental refusal and severe psychoneurotic disorders should also be considered as contraindications.

EQUIPMENT AND SAFETY CONDITIONS

SELECTION OF SUITABLE EQUIPMENT FOR PLEXUS AND MIXED NERVES BLOCKS

Mixed nerves trunks and plexuses are best localized by using electrical stimulation to elicit twitches in supplied muscles. The intensity of delivered current is critical and has been prospectively evaluated during humeral blocks in adults.[33] This recent publication confirms previous empirical findings: muscle twitches should be elicited at intensities ranging from 0.5 to 0.8 mA to guarantee high success rate (>95%) of blockade. Sheathed needles of adequate length are the most appropriate for both safety and precision, provided they have a short-bevel or a pinpoint tip. More sophisticated devices have recently been suggested to allow insertion of a catheter either through a cannula mounted over a metallic blunt needle, or directly through the insulated needle connected to a nerve stimulator. More recently, the catheter itself, with a built-in spiraled metallic wire, can be connected to the nerve stimulator, thus allowing its precise placement in close contact to the relevant nerve path. These catheters can be connected to infusion pumps or inflatable bags allowing precise delivery of LA, either continuously or on-demand, over long periods of time.

SELECTION OF A SUITABLE EQUIPMENT FOR COMPARTMENT BLOCKS

Precise identification of fascial planes is the essential step of compartment blocks such as the fascia iliaca compartment block. To achieve this goal, it is necessary to use a short-beveled needle that allows good identification of the relevant fascial plane. Using this kind of needle also improves considerably the safety of the procedure. Several commercially available short-beveled needles, including pediatric Tuohy needles, allow safe placement of a catheter along the inner surface of the relevant fascial plane, thus permitting continuous infusion or intermittent injections of anesthetic solutions for both passive and active (reeducation and joint mobilization) postoperative pain relief.

SELECTION OF THE LOCAL ANESTHETIC SOLUTION

Local anesthetics of the amide type are the most commonly used local anesthetics. Usual solutions and doses (according to patient's weight) are displayed in **Table 1**. The limited duration of action of local anesthetics can be significantly prolonged by a sound selection of additives mixed with the injected solution. Alpha2-adrenergic agonists have long been added to local anesthetics. Epinephrine is the most commonly used of such agents, usually in concentrations ranging from 1:200,000 to 1:400,000; when not contraindicated, this addition offers two main advantages: 1) vascular absorption is decreased; 2) detection of inadvertent intravascular injection is facilitated by monitoring the electrocardiographic tracing. Provided that adequate time is allowed (20 seconds), and at least 0.5 µg/Kg of epinephrine is used, intravascular injection can be recognized by ST segment elevation, T wave change [34] and, occasionally, heart rate change.[35]

Clonidine, an α2-adrenergic agonist, is now commonly added to local anesthetics. Administered at doses ranging from 1 to 1.5 µg/Kg, clonidine consistently increases the duration of nerve blockade [36,37] with no perceptible hemodynamic effects in children. This dose may produce a slight sedation for 1 to 3 hours, a beneficial effect that allows for a smoother emergence from general anesthesia. While the addition of sodium bicarbonate aiming at increasing the non-ionized form of the local anesthetic has not proved to be of significant clinical relevance [38], the addition of ketamine appears promising.[39] However, more clinical studies are needed before ketamine can be suggested for routine use in peripheral nerve blockade.

AVOIDING COMPLICATIONS

Experience and proper training of the anesthesia team are of paramount importance when performing peripheral nerve blocks. These blocks in children should only be performed in an operating theater environment with the same monitoring and other safety procedures recommended for a general anesthetic. Prior to any block performance, establishment of an intra-venous line [40] and cardiovascular monitoring (i.e., EKG, blood pressure, respiratory rate and pulse oxymetry) must be instituted. Vital signs as well as the agents, doses and techniques used should be recorded on a complete anesthesia chart.

While peripheral nerve blocks in adults are typically performed in conscious, lightly sedated patients,

most children fear needle punctures and thus require a heavy sedation or a general anesthetic for block performance. If not contraindicated for medical reasons (poor physical status, full stomach etc.), light general anesthesia can be safely used and is both very commonly practiced and widely accepted in pediatric anesthesia practice [41]. The technique of injection is a key factor of safety and early diagnosis of complications. All block procedures require that an aspiration test and evaluation of a test dose (with 0.5 to 1 µg/Kg of epinephrine if not contra-indicated) be performed before large amounts of local anesthetic are injected. The injection must be performed slowly and any unusual resistance requires immediate cessation of the technique.

TECHNIQUES

LUMBAR PLEXUS BLOCKS (PSOAS COMPARTMENT BLOCKS)

Lumbar plexus blocks aim at injecting a local anesthetic within the psoas compartment where the lumbar plexus lies. The child is placed in the semiprone position, resting on the non-operated side. Two sites for needle insertion can be used (42) (Figure 1): 1) the midpoint of the line joining the spinous process of L5 to the posterior iliac spine (modified Chayen's technique) or 2) the intersection of the line joining the two iliac crests with the line parallel the major axis of the spine drawn from the posterior iliac spine (Winnie's technique). However, it should be noted that a slightly more medial site of puncture (1 cm medial to the intersection, on the intercrystal line) improves the technique. With either approach, the insulated block needle is inserted at right angles to the skin until twitches are elicited in the quadriceps muscle.

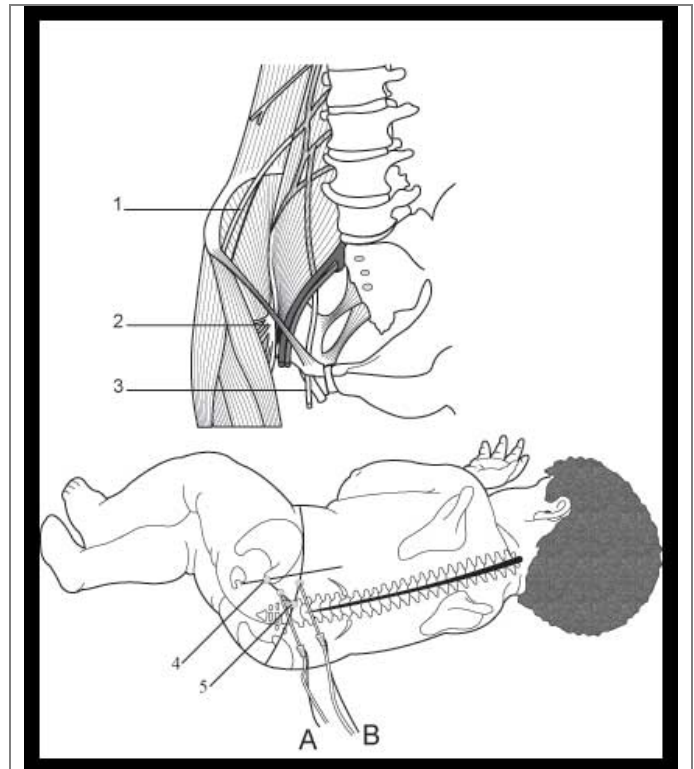


Figure 1. *Direct lumbar plexus blocks*

A: Modified Chayen's technique

B: Modified Winnie's technique

1. Lateral cutaneous nerve of the thigh

2. Femoral nerve

3. Obturator nerve

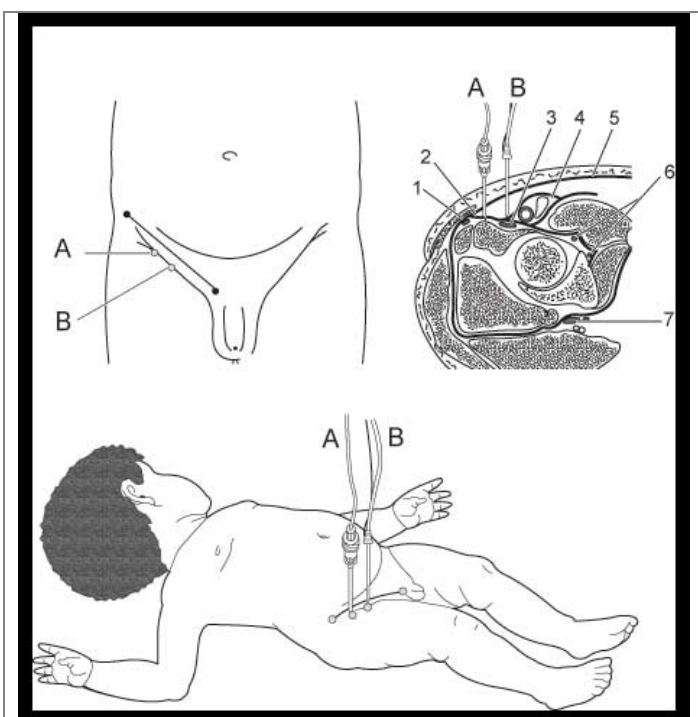
4. Posterior superior iliac spine

5. Spinous process of L5

When long lasting pain relief is sought, a catheter can be inserted within the psoas compartment, using an appropriate device [43,44] and a 5 mL/h continuous infusion of 0.125% bupivacaine or 0.2% ropivacaine in children weighing more than 30 Kg usually provides excellent analgesia (this dose can be adjusted by titration later on). It should be noted that the blockade can occasionally involve spread to the epidural or subarachnoid space, a complications once more frequent before the advent of insulated block needles [42]. Nevertheless, this potential side effect has to be considered when selecting this technique and the injected

Table 2: Commonly used volumes of local anesthetic for usual lower extremity nerve blocks (single shot procedures)

Approach	2-10 kg	15 kg	20 kg	25 kg	30 kg	40 kg	50 kg	60 kg and above
Lumbar plexus	1 mL/kg	15 mL	20 mL	20 mL	20 mL	20 mL	20 mL	20 mL
Femoral	0.7 mL/kg	8 mL	12 mL	15 mL	15 mL	17.5 mL	20 mL	25 mL
Fascia iliaca	1 mL/kg	12.5 mL	15 mL	17.5 mL	20 mL	22.5 mL	25 mL	30 mL
Popliteal	0.3 mL/kg	5 mL	6.5 mL	8 mL	10 mL	12 mL	15 mL	18-20 mL

**Figure 2: Femoral nerve and fascia iliaca compartment block**

- A. Fascia iliaca compartment block
 B. Femoral nerve block
 1. Lateral cutaneous nerve of the thigh
 2. Fascia iliaca
 3. Femoral nerve
 4. Femoral vessels sheath
 5. Fascia lata

volume of local anesthetic should not exceed 20 mL (Table 2). Finally, due to the possible complications arising from intraperitoneal insertion of the needle, the indications of direct lumbar plexus blocks should be reserved to unilateral major surgery involving the hip, femur bone and thigh, and the knee.

FEMORAL NERVE BLOCK

Femoral nerve block is perhaps the simplest peripheral nerve block of the lower extremity. With the child lying supine, the block needle is inserted vertically through the skin 0.5 to 1 cm both below the inguinal ligament and lateral to the femoral artery until twitches of the quadriceps

muscle are elicited (Figure 2). The technique is particularly suitable for providing intra and post-operative pain relief in children with a femoral shaft fracture or children undergoing elective surgery in areas supplied by the femoral nerve. Long-lasting analgesia is easily obtained by placing a catheter along the nerve path and injecting a local anesthetic, either continuously or on-demand.[45,46] Typical infusion rates used by this author can be seen in Table 3. Although clinical infections are very rare, bacterial contamination of the catheter is frequent and requires that strict antibacterial precautions be taken on insertion of such devices and that the catheters be removed when adequate pain relief can be obtained by oral analgesics.[30]

FASCIA ILIACA COMPARTMENT BLOCK

The technique aims at injecting a local anesthetic at the inner surface of the fascia iliaca, expecting its spread towards the lumbar plexus nerves as they emerge from the psoas compartment. The child is placed in the dorsal recumbent position. A short-beveled needle is inserted perpendicularly to the skin, 0.5-1 cm below the union of the lateral with the two medial thirds of the skin projection of the inguinal ligament (Figure 2). A first give (crossing of the fascia lata) then a second one (crossing of the fascia iliaca), each followed by a loss of resistance, are sought before the local anesthetic is injected (Table 2). Distribution of anesthesia involves the territories of the femoral and lateral cutaneous nerves. In addition, the obturator nerve is blocked in approximately 80% of cases. The technique is extremely easy to perform and safe. Introducing a catheter below the fascia iliaca allows continuous or discontinuous infusion of local anesthetics which permits long lasting or intermittent analgesia (wound dressings, joint mobilization, etc) (21,44). Continuous infusions are usually performed using 0.125% bupivacaine or 0.2% ropivacaine at rates ranging from 5 to 10 mL/h (this dose can be adjusted by titration later on) and/or on-demand top up doses, allowing patient-controlled analgesia are well appreciated even by rather young patients (from 6 years of age approximately). The use of more concentrated solutions and larger infusion volumes

can occasionally be administered without significantly increasing the danger of systemic toxicity.

SAPHENOUS/VASTUS MEDIALIS NERVE BLOCK

Several techniques of saphenous nerve block have been described in the literature: their common feature is a rather high failure rate (well over 20%) due to the difficulties in localization of the nerve (most techniques are "blind" infiltrations). The saphenous nerve is a purely sensory nerve; thus it cannot be located by electrical stimulation. However, since it runs within the same fascial gutter as that containing the motor nerve supplying the vastus medialis muscle, nerve stimulation can be used to identify the motor nerve [47]. For the nerve stimulation technique, the child is placed supine. The landmarks are the inguinal ligament, the femoral artery and the upper border of the sartorius muscle (Figure 3). A short, short-beveled insulated needle is inserted perpendicularly to the skin, 0.5 cm lateral to the femoral artery just above the upper border of the sartorius until twitches are elicited in the vastus medialis muscle. At this point, 0.1 to 0.2 mL/Kg of local anesthetic is injected, which results in blockade of both the vastus medialis nerve and the saphenous nerve.

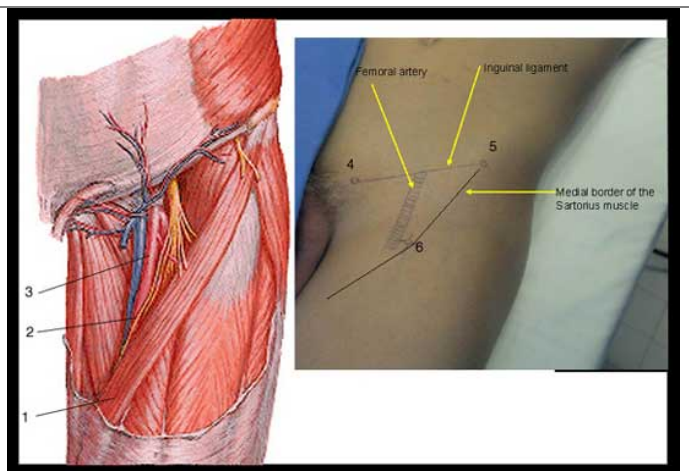


Figure 3. Saphenous/vastus medialis nerve block

1. Sartorius muscle (lateral border)
2. Saphenous nerve
3. Femoral artery
4. Pubic spine (or tubercle)
5. Anterior superior iliac spine
6. Site of puncture

PROXIMAL SCIATIC NERVE BLOCKS

Four main proximal techniques are suitable for approaching the sciatic nerve [48].

Posterior approach

The child is placed in the lateral decubitus position, resting on the non-operated side. The landmarks are the greater trochanter of the femur and the end of the coccyx (Figure 4). The site of puncture is the midpoint of the line joining the two landmarks. The block needle is inserted at right angles to the skin, i.e., both medially and ventrally, pointing to the ischial tuberosity, until twitches are elicited in the leg and/or the foot.

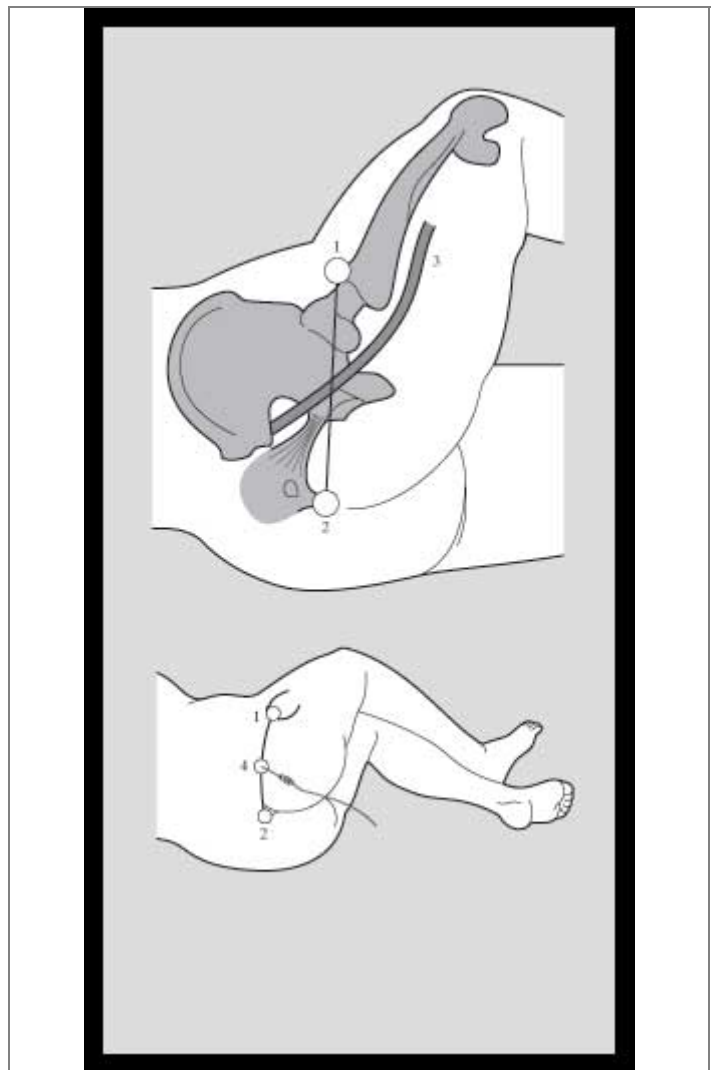


Figure 4. Proximal posterior approach to the sciatic nerve

1. Greater trochanter of the femur
2. Coccyx
3. Sciatic nerve
4. Site of puncture

Anterior approach

The anterior approach to the sciatic nerve has been described for use in patients who can not be

positioned in the lateral decubitus position [49,50]. Two important landmarks for this block include: the inguinal ligament and the greater trochanter of the femur. Determination of the site of needle insertion requires that two lines be drawn: 1) one line parallel to the inguinal ligament passing over the greater trochanter, and 2) the second line parallel to the major axis of the body passing over the union of the medial one third with the lateral two thirds of the inguinal ligament (**Figure 5**). The needle insertion site corresponds to the intersection of the two lines. Several attempts have been made to simplify the location of the puncture site, but their applicability to young children remains questionable [51,52].

The needle is inserted almost perpendicularly to the skin toward the medial edge of the femur (supposedly the lesser trochanter of the femur) until twitches are elicited in the foot. This technique is consistently more difficult than the posterior approach, can result in inadvertent puncture of the femoral vessels and should be reserved for patients in whom that posterior approach can not be used.

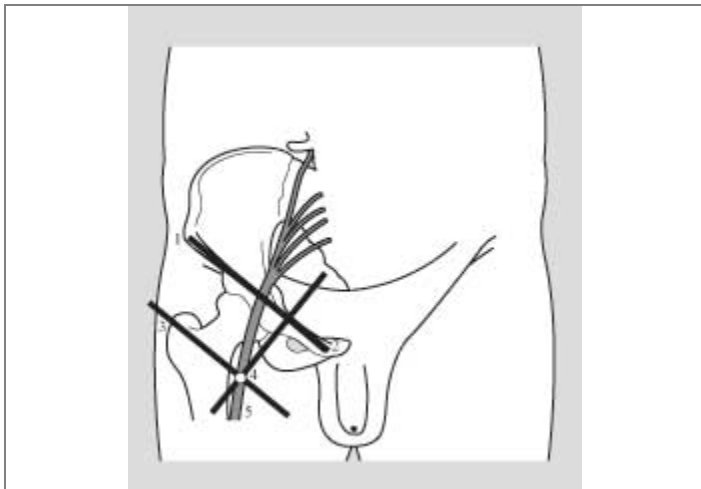


Figure 5. Proximal anterior approach to the sciatic nerve

1. Anterior superior iliac spine
2. Pubic spine (or tubercle)
3. Greater trochanter of the femur
4. Site of puncture
5. Sciatic nerve

Frontal ischial approach

A frontal approach aiming at penetrating the subgluteal space where the sciatic nerve runs has been described by Raj et al. [53] and used in children for many years. This technique has recently gained a renewed interest in adults [54,55]. The patient is placed supine and the legs are flexed over the pelvic girdle (usually by an

aid); this positioning is very easily achieved in infants, whilst it is more difficult to sustain in grown up children and adolescents (**Figure 6**). The site of puncture is the midpoint of the line joining the greater trochanter and the ischial tuberosity. The block needle is introduced perpendicularly to the skin, in direction to the lateral border of the ischial tuberosity, i.e., medially and cranially until muscle twitches are elicited in the foot. If the needle contacts the ischial tuberosity without any twitches, it should be withdrawn and reinserted slightly more laterally.

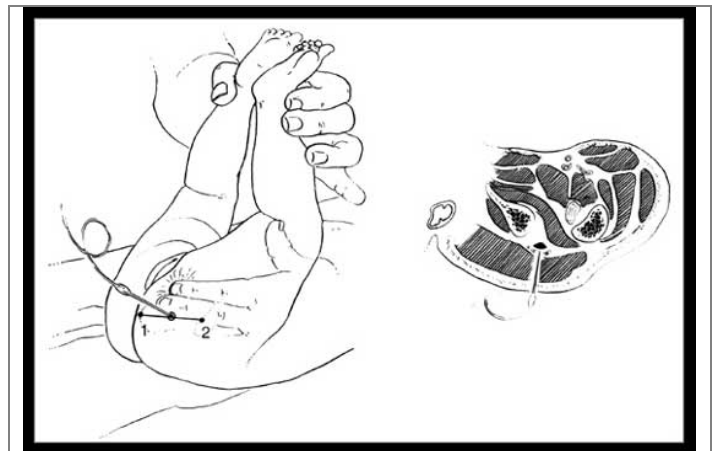


Figure 6. Proximal frontal approach to the sciatic nerve

1. Ischial tuberosity
2. Greater trochanter of the femur

Lateral approach

A lateral approach has been described for use in patients lying supine [56] with the leg slightly medially rotated. There is only one landmark which is the greater trochanter of the femur. The needle is inserted horizontally 1 to 2 cm below the lateral skin projection of the greater trochanter in order to pass just below the lower border of the femur (**Figure 7**). If bone contact is made, the needle is withdrawn and re-inserted slightly more posteriorly until twitches are elicited in the foot. In recent years, this technique has elicited several publications in adult patients. It is suitable for catheter placement [57], but requires excellent immobilization of the lower extremity during the postoperative period in order to avoid inadvertent catheter removal.

All these proximal approaches require the same amount of local anesthetic (rather large) as indicated in Table 1. Infusion regimens for continuous blockade are displayed in Table 3. They result in the same distribution of anesthesia which includes the territory of the sciatic nerve but also, in virtually all pediatric patients, that supplied by

the posterior femoral nerve block (i.e., the dorsal part of the thigh).

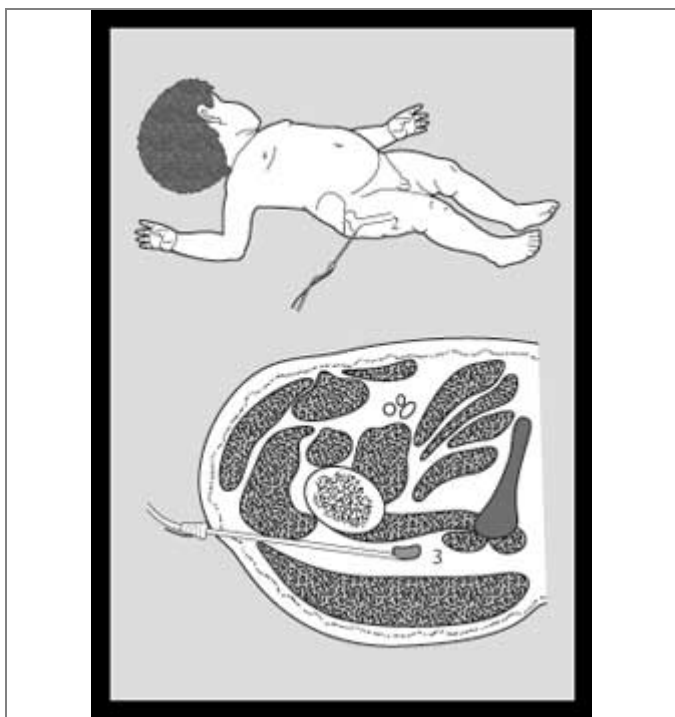


Figure 7. Proximal lateral approach to the sciatic nerve

1. Greater trochanter of the femur
2. Femur
3. Sciatic nerve

SCIATIC NERVE BLOCK IN THE POPLITEAL FOSSA

The popliteal approach to the sciatic nerve is an excellent choice of analgesia in patients under-going leg and foot surgery. There are virtually no contraindications to this block procedure and the quality of analgesia is remarkably high with a duration lasting longer than that of any other conduction block performed with the same local anesthetic [15]. The sciatic nerve is approached with the child in the prone or, preferably, the semi-prone position with the limb to be blocked lying upper-most [32]. The landmarks are the borders of the popliteal fossa, i.e., the tendon of the biceps femoris muscle laterally and the tendons of the semimembranosus and semitendinosus muscles medially (**Figure 8**). The site of puncture lies approximately 1 cm below the summit of the popliteal fossa and 0.5 cm lateral to the bisecting line of its upper angle (to avoid puncturing the popliteal artery). In fact, finger palpation of the upper part of the popliteal fossa finds a clearly perceptible dimple at the center of which the block needle will be introduced. The needle is inserted cephalad at a 45-60° angle to the skin until twitches are elicited in

the foot. The nerves lie below the popliteal membrane, the piercing of which can be identified by a characteristic "click", which can even be sought by a loss-of-resistance technique. Recommended volumes of local anesthetic are listed in **Table 2** and **Table 3**. A catheter can easily be introduced for providing long-lasting pain relief, which makes the technique the indication of choice for both intra and postoperative management of clubfoot surgery.

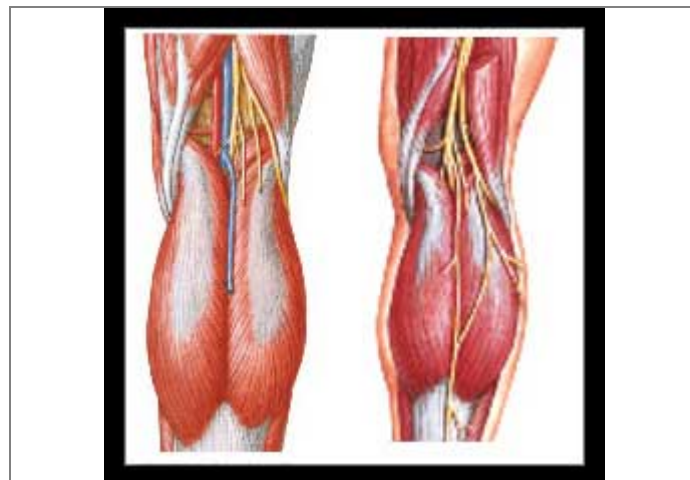


Figure 8. Popliteal approach to the sciatic nerve

1. Tendon of the biceps femoris muscle
2. Tendons of the semimembranosus and semi-tendinosus muscles

METATARSAL BLOCK

The metatarsal block is a simple and suitable block procedure providing good pain relief following surgical procedures on the toes [58]. It is typically carried out with the patient lying supine. A standard IM needle is inserted through the dorsum of the foot (**Figure 9**) and advanced in close contact with the medial border of the base of the metatarsal up to the sole. When the distal extremity of the needle is felt and seen as it pushes the skin of the sole, the local anesthetic is injected while the needle is slowly withdrawn. A volume of 1 to 3 mL of 0.25-0.5% plain bupivacaine or 0.2-0.5% ropivacaine is injected. The same procedure is repeated along the lateral border of the same metatarsal to provide full anesthesia of the relevant toe.

A still simpler technique for toe surgery consists of injecting a LA within the fibrous sheath which surrounds the synovial sheath of the flexor tendon of each toe and within which digital nerves supplying the toe are located. While the child is placed supine, the anesthesiologist locates by palpation the head of the relevant metatarsal bone on the sole of the foot. An intradermic needle is

inserted perpendicularly to the skin, right in the center of the skin projection of this metatarsal head, until bone contact is made. To avoid sub-periosteal injection, the needle is then slightly with-drawn before injecting 1-3 mL of LA (until resistance is felt). Within 2 minutes all the nerves supplying the relevant toe are fully anesthetized in virtually all patients, thus allowing pain free surgery and postoperative pain relief for several hours. Both these techniques have many advantages over the "classical" ring block: they are safer (no terminal artery in close proximity, virtually no complication), simpler and less painful in conscious patients (even though injection is not pain-free). Caution should be taken in case of infection to avoid bacterial contamination of the synovial sheath (in this case, the technique should be considered contra-indicated).

well established that children experience pain and remember it to the same extent as adults do, adequate strategies of pain management in pediatrics and training necessary for its successful implementation are still lacking in institutions. While neuraxial block procedures have long been established in pediatric anesthesia, specific nerve blocks, particularly blocks of the lower extremity remain despite their excellent benefit/risk ratio. Single shot nerve block procedures are appropriate for many indications of pediatric surgery, including patients undergoing ambulatory surgery. The future holds promise for the wider use of indwelling catheter techniques and their impact on postoperative analgesia and health care economics.

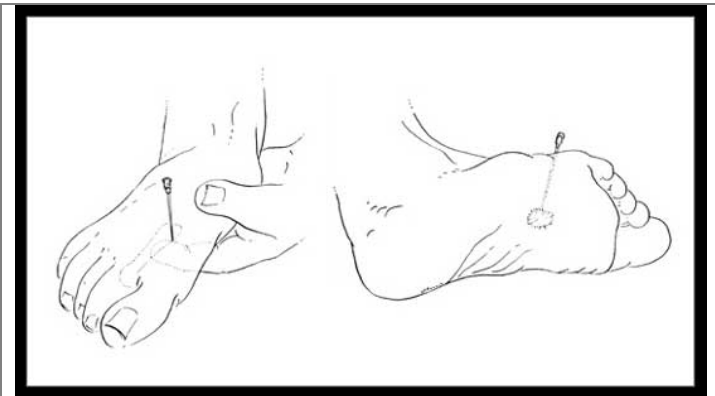


Figure 9. *Metatarsal block*

SUMMARY

The management of intra and postoperative pain in children requires a rational approach, aiming to maximize both patient's comfort and safety. Although it is

REFERENCES

1. Dalens BJ. Regional anesthetic techniques. In Bissonnette B & Dalens B (eds): Pediatric Anesthesia: Principles and Practice. McGraw Hill, New York 2002; p 528-575.
2. Laulin JP, Celerier E, Larcher A, Le Moal M, Simonnet G. Opiate tolerance to daily heroin administration: an apparent phenomenon associated with enhanced pain sensitivity. *Neuroscience* 1999;89:631-6.
3. Celerier E, Rivat C, Jun Y, Laulin JP, Larcher A, Reynier P, Simonnet G. Long-lasting hyperalgesia induced by fentanyl in rats: preventive effect of ketamine. *Anesthesiology* 2000;92:465-72.
4. Gardell LR, Wang R, Burgess SE, Ossipov MH, Vanderah TW, Malan TP Jr, Lai J, Porreca F. Sustained morphine exposure induces a spinal dynorphin-dependent enhancement of excitatory transmitter release from primary afferent fibers. *J Neurosci* 2002;22:6747-55.
5. Hayes C, Molloy AR. Neuropathic pain in the perioperative period. *Int Anesthesiol Clin*. 1997; 35:67-81.